



Complete Biochemical Remission With Oral Vancomycin in a Patient With Primary Sclerosing Cholangitis and High Serum Immunoglobulin G4 Levels

Aalam Sohal, MD¹, and Kris V. Kowdley, MD, FACP^{1,2}

¹Liver Institute Northwest, Seattle, WA

²Elson Floyd College of Medicine, Spokane, WA

ABSTRACT

Primary sclerosing cholangitis (PSC) is a progressive cholestatic liver disease characterized by intrahepatic and extrahepatic bile duct strictures leading to cirrhosis. A subtype with elevated serum immunoglobulin (Ig) G4 levels has been recently identified. Elevated IgG4 titers can be present in 9%–15% of patients with PSC. Currently, liver transplantation is the only effective treatment of PSC, although multiple medical therapies are under evaluation. We report a case of a young adult with PSC and elevated IgG4 levels who had marked serum aminotransferase elevation; the patient had an incomplete response to steroids but achieved complete biochemical remission after initiation of oral vancomycin.

KEYWORDS: primary sclerosing cholangitis; vancomycin; IgG4; PSC

INTRODUCTION

Primary sclerosing cholangitis (PSC) is a cholestatic disease that can lead to recurrent episodes of cholangitis and cirrhosis.¹ PSC has been categorized into large-duct, small-duct forms, and a variant that overlaps with autoimmune hepatitis.² Recently, a subtype of PSC with high serum immunoglobulin (Ig) G4 (PSC-IgG4 subtype) has been described.² Previous studies have reported that 9%–15% of patients with PSC have elevated IgG4.^{3–5} Studies have suggested that patients with PSC-IgG4 subtype have a shorter time to cirrhosis decompensation and liver transplantation than patients with normal IgG4 levels.⁶ Currently, liver transplantation is the only definitive treatment; however, various medical therapies are currently under evaluation for PSC. There is a paucity of data regarding the management of patients with PSC-IgG4 subtype. Some retrospective studies have suggested corticosteroids to be beneficial in this subtype; however, no clinical trial has been conducted to identify its efficacy.^{3,7} We present a case of a 20-year-old man with the PSC-IgG4 subtype who did not achieve biochemical remission with corticosteroids but achieved biochemical remission with oral vancomycin (OV).

CASE REPORT

A 20-year-old man recently diagnosed with ulcerative colitis (UC) was referred to our clinic due to dull right upper quadrant abdominal pain and elevated liver enzymes. He denied fever, chills, night sweats, pruritus, fatigue, icterus, or dark urine. On his presentation, his liver function tests revealed normal total bilirubin, alanine transaminase (ALT) of 325 IU/mL, aspartate transaminase (AST) of 124 IU/mL, and alkaline phosphatase (ALP) of 259 IU/mL. He underwent extensive workup to rule out common causes of liver disease, including viral etiologies, Wilson disease, celiac disease, and autoimmune hepatitis. His workup was negative, except for an anti-smooth muscle antibody of 1:40 but a normal IgG of 1,603 mg/dL. His serum IgG4 was noted to be 231.9 mg/dL on presentation (upper limit of normal [ULN]: 86 mg/dL). Magnetic resonance cholangiopancreatography (MRCP) revealed patchy peribiliary enhancement and multifocal narrowing in small intrahepatic bile ducts. Because of disproportionately elevated ALT and positive anti-smooth muscle antibody, a liver biopsy was performed to rule out overlap syndrome. Biopsy revealed ductular reaction, bile duct distortion, periportal chronic inflammation, and periportal fibrosis without any interface hepatitis.

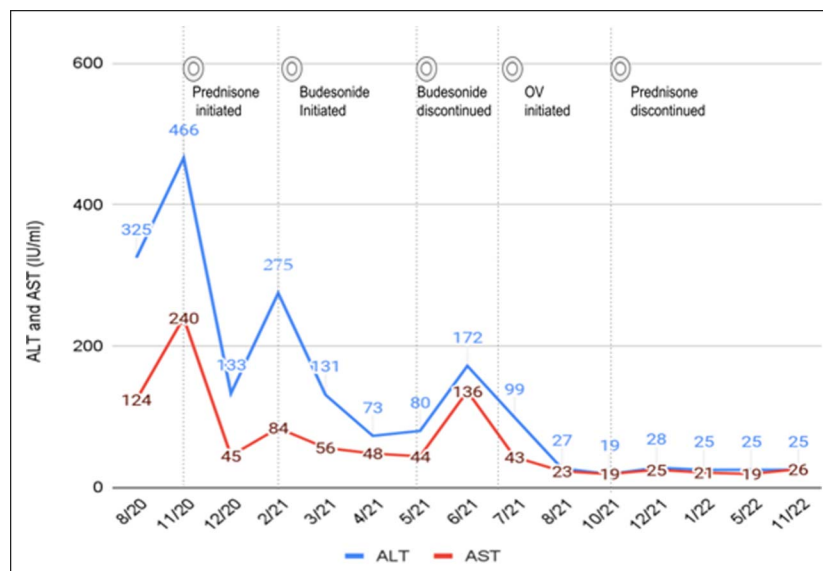


Figure 1. ALT and AST trends in relation to changes in medications. ALT, alanine transaminase; AST, aspartate transaminase; OV, oral vancomycin

He was initiated on prednisone 40 mg for the treatment of PSC-IgG4 subtype. One month after initiation, his liver enzymes improved (ALT: 133, AST: 45, and ALP: 152) (Figures 1 and 2). The patient's liver enzymes increased again when his dose was decreased. Budesonide was initiated with the goal to wean off prednisone. However, the liver enzymes continued to be elevated after the initiation of budesonide. Budesonide was discontinued, and the patient was maintained on a dose of prednisone of 20 mg per day. After discussion regarding the risks and benefits of OV as well as other immunomodulatory agents, OV 500 mg 3 times a day was initiated. The patient achieved complete normalization of his liver enzymes a month after initiation of OV. The patient was subsequently weaned off prednisone 3 months after initiation of OV and has been in remission

for over 12 months. An improvement in his IgG4 levels was also noted (Figure 3). Throughout the course, his ulcerative colitis was in remission with the use of mesalamine, and the patient did not experience any changes in his clinical status.

DISCUSSION

Current American Association for the Study of Liver Diseases and American College of Gastroenterology guidelines recommend that serum IgG4 levels should be measured at least once in patients with PSC to differentiate PSC from IgG4-related sclerosing cholangitis (IgG4-SC).^{1,8} IgG4-SC is common in older men and serum IgG4 levels are typically 4 times the ULN.^{4,9} This condition is associated with autoimmune pancreatitis but is

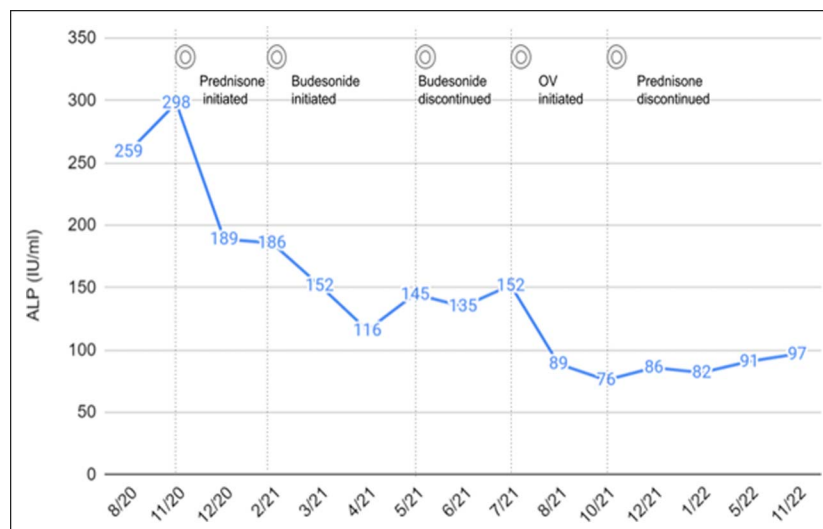


Figure 2. ALP trend in relation to changes in medications. ALP, alkaline phosphatase; OV, oral vancomycin.

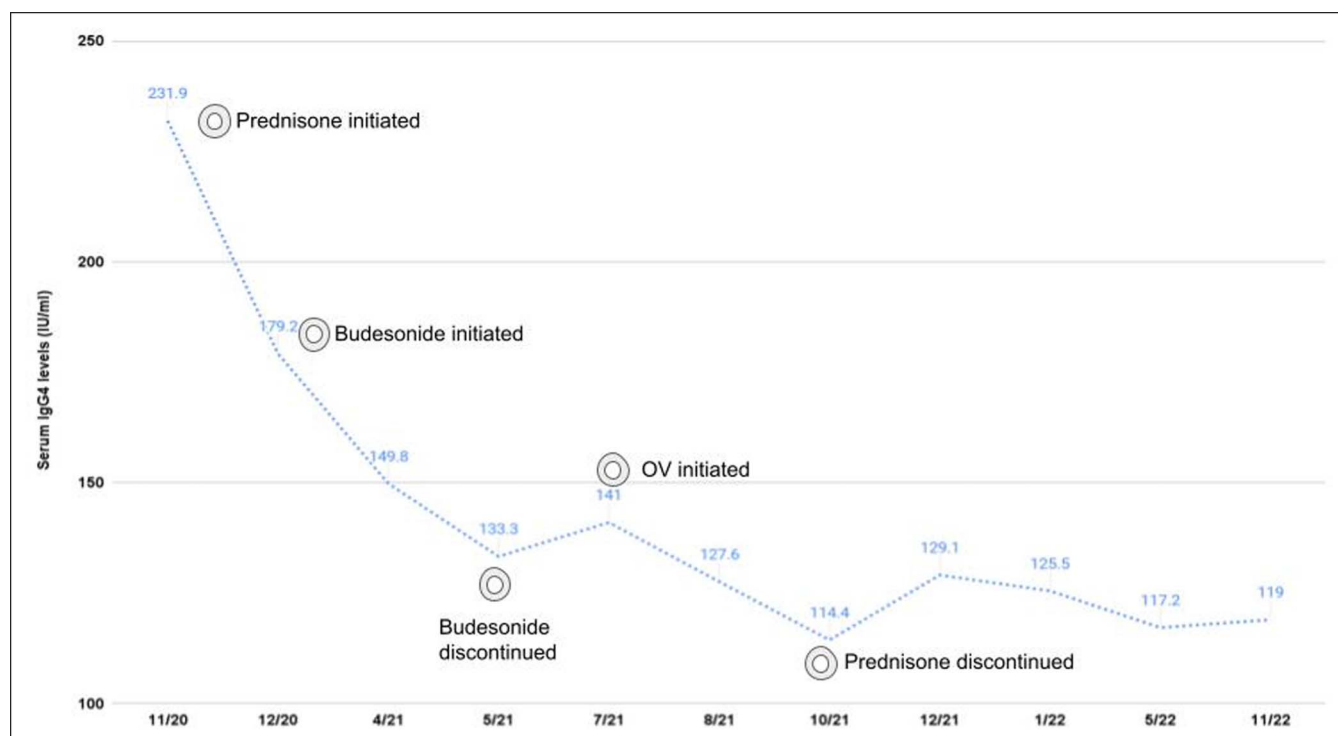


Figure 3. Serum IgG trend in relation to changes in medications. Ig, immunoglobulin.

rarely observed in patients with UC.² The diagnosis of IgG4-SC is usually made on liver biopsy. However, IgG4 staining was not performed in our case, which is a limitation. In our case, the patient's young age, presence of UC, absence of pancreatic involvement, and serum IgG4 levels less than 4 times ULN made the diagnosis of the PSC-IgG4 subtype more likely.

Currently, there is no approved treatment for the management of PSC, except liver transplantation.^{1,8} Ursodeoxycholic acid (UDCA) has been shown to improve liver biochemistry but does not affect clinical outcomes in PSC.^{10,11} UDCA was felt to be unlikely to help given the marked elevation of ALT and AST levels. Although corticosteroids are not beneficial in typical PSC, small studies have reported its beneficial role in PSC-IgG4 subtype.^{3,7} Based on this evidence, prednisone 40 mg was initiated. The patient had improvement in his liver enzymes; however, we were unable to taper steroids to an acceptable level. Budesonide use was also not beneficial. We, therefore, started OV as an alternate therapy. This allowed us to achieve a complete biochemical remission and discontinue steroid therapy.

Studies have suggested that gut microbiota plays a role in the pathogenesis of PSC.¹² Enterohepatic circulation of microbial pathogens may result in biliary inflammation and scarring.¹³ As a result, antibiotics are being evaluated as therapeutic options for patients with PSC.¹⁴ OV is gut-selective and multiple case reports have documented its use to be associated with biochemical improvement in patients with PSC.^{15–17} Hey et al¹⁵ reported improvement in liver enzymes with the use of OV in a patient with recurrent PSC. Buness et al¹⁶ reported the normalization of liver

enzymes after treatment with OV in a 15-year-old girl with PSC. Davies et al¹⁷ reported a case of a 12-year-old girl with recurrent PSC who achieved biochemical remission and had a normal biopsy 3 years after treatment with OV. A study by Deneau et al¹⁸ comparing OV with ursodiol and placebo failed to show any clinical benefit of OV or UDCA over placebo. Interestingly, our patient not only achieved biochemical remission with OV but also had an improvement in IgG4 levels.

The mechanism behind the biochemical improvement with the use of OV in patients with PSC is unknown. However, several explanations have been proposed. Abarbanel et al¹⁹ suggested OV to have immunomodulatory effects in the gut. OV increases T-regulatory cells, a key regulator of inflammation at mucosal surfaces.¹⁹ Vaughn et al,²⁰ in their study of patients with PSC and inflammatory bowel disease, reported OV to reduce the production of secondary bile acids and fecal microbiota diversity.

In conclusion, there is an unmet need for therapeutic options for patients with PSC. Our case suggests that OV may be beneficial in achieving biochemical remission in patients with PSC-IgG4 subtype.

DISCLOSURES

Author contributions: A. Sohal: responsible for writing the draft. KV Kowdley: responsible for patient evaluation and critical revisions; is the article guarantor.

Financial disclosure: A. Sohal has no conflicts of interest or financial disclosures. KV Kowdley declares research support

from CymaBay Therapeutics; grants and/or contracts from 89Bio, Genfit, Gilead, GlaxoSmithKline, Hanmi, HighTide, Intercept, Madrigal, Mirum, NGM, Pfizer, Pliant, and Viking; royalties/licenses from UpToDate; consulting fees from 89Bio, Calliditas Therapeutics, CymaBay Therapeutics, Genfit, Gilead, Inipharm, Intercept, Madrigal, Mirum, NGM, and Pliant; payment/honoraria for lectures, presentations, speakers bureaus, manuscript writing, or educational events from AbbVie, Gilead, and Intercept; participation in a data safety monitoring board or advisory board for CTI, Medpace and Labcorp; stock or stock options for Inipharm; and receipt of equipment, materials, drugs, medical writing, gifts, or other services from Sonic Insight. The authors confirm that informed patient consent was obtained to publish the case details.

Informed consent was obtained for this case report.

Received August 23, 2023; Accepted December 13, 2023

REFERENCES

- Lindor KD, Kowdley KV, Harrison ME; American College of Gastroenterology. ACG clinical guideline: Primary sclerosing cholangitis. *Am J Gastroenterol.* 2015;110(5):646–60.
- Manganis CD, Chapman RW, Culver EL. Review of primary sclerosing cholangitis with increased IgG4 levels. *World J Gastroenterol.* 2020;26(23):3126–44.
- Mendes FD, Jorgensen R, Keach J, et al. Elevated serum IgG4 concentration in patients with primary sclerosing cholangitis. *Am J Gastroenterol.* 2006;101(9):2070–5.
- Boonstra K, Culver EL, de Buy Wenniger LM, et al. Serum immunoglobulin G4 and immunoglobulin G1 for distinguishing immunoglobulin G4-associated cholangitis from primary sclerosing cholangitis. *Hepatology.* 2014;59(5):1954–63.
- Fischer S, Trivedi PJ, Ward S, Greig PD, Therapondos G, Hirschfield GM. Frequency and significance of IgG4 immunohistochemical staining in liver explants from patients with primary sclerosing cholangitis. *Int J Exp Pathol.* 2014;95(3):209–15.
- Peerani F, Du L, Lytvyak E, et al. Serum IgG4 cut-off of 70 mg/dL is associated with a shorter time to cirrhosis decompensation and liver transplantation in primary sclerosing cholangitis patients. *Can Liver J.* 2022;5(1):31–42.
- Björnsson E, Chari S, Silveira M, et al. Primary sclerosing cholangitis associated with elevated immunoglobulin G4: Clinical characteristics and response to therapy. *Am J Ther.* 2011;18(3):198–205.
- Bowlus CL, Arrivé L, Bergquist A, et al. AASLD practice guidance on primary sclerosing cholangitis and cholangiocarcinoma. *Hepatology.* 2023;77(2):659–702.
- Culver EL, Sadler R, Simpson D, et al. Elevated serum IgG4 levels in diagnosis, treatment response, organ involvement, and relapse in a prospective IgG4-related disease UK cohort. *Am J Gastroenterol.* 2016;111:733–43.
- European Association for the Study of the Liver. EASL clinical practice guidelines: Management of cholestatic liver diseases. *J Hepatol.* 2009;51(2):237–67.
- Lindor KD. Ursodiol for primary sclerosing cholangitis. Mayo Primary Sclerosing Cholangitis-Ursodeoxycholic Acid Study Group. *N Engl J Med.* 1997;336(10):691–5.
- Pontecorvi V, Carbone M, Invernizzi P. The “gut microbiota” hypothesis in primary sclerosing cholangitis. *Ann Transl Med.* 2016;4(24):512.
- Tabibian JH, O’Hara SP, Lindor KD. Primary sclerosing cholangitis and the microbiota: Current knowledge and perspectives on etiopathogenesis and emerging therapies. *Scand J Gastroenterol.* 2014;49(8):901–8.
- Elfaki DA, Lindor KD. Antibiotics for the treatment of primary sclerosing cholangitis. *Am J Ther.* 2011;18(3):261–5.
- Hey P, Lokan J, Johnson P, Gow P. Efficacy of oral vancomycin in recurrent primary sclerosing cholangitis following liver transplantation. *BMJ Case Rep.* 2017;2017:bcr2017221165.
- Buness CW, Johnson KM, Ali AH, et al. Successful response of primary sclerosing cholangitis and associated ulcerative colitis to oral vancomycin may depend on brand and personalized dose: Report in an adolescent. *Clin J Gastroenterol.* 2021;14(2):684–9.
- Davies YK, Tsay CJ, Caccamo DV, Cox KM, Castillo RO, Cox KL. Successful treatment of recurrent primary sclerosing cholangitis after orthotopic liver transplantation with oral vancomycin. *Case Rep Transplant.* 2013;2013:314292.
- Deneau MR, Mack C, Mogul D, et al. Oral vancomycin, ursodeoxycholic acid, or no therapy for pediatric primary sclerosing cholangitis: A matched analysis. *Hepatology.* 2021;73(3):1061–73.
- Abarbanel DN, Seki SM, Davies Y, et al. Immunomodulatory effect of vancomycin on Treg in pediatric inflammatory bowel disease and primary sclerosing cholangitis. *J Clin Immunol.* 2013;33(2):397–406.
- Vaughn BP, Kaiser T, Staley C, et al. A pilot study of fecal bile acid and microbiota profiles in inflammatory bowel disease and primary sclerosing cholangitis. *Clin Exp Gastroenterol.* 2019;12:9–19.

Copyright: © 2024 The Author(s). Published by Wolters Kluwer Health, Inc. on behalf of The American College of Gastroenterology. This is an open access article distributed under the terms of the Creative Commons Attribution-Non Commercial-No Derivatives License 4.0 (CCBY-NC-ND), where it is permissible to download and share the work provided it is properly cited. The work cannot be changed in any way or used commercially without permission from the journal.